



PATIENT PRESENTING CLINICAL SIGNS

Brody Spagna CT scan for evaluation of oral mass noted last week. Patient had a TPLO 2 weeks ago. Mobile teeth noted and removed at this time. Biopsy performed showed Fibrosarcoma.

SPECIES COMPUTED TOMOGRAPHIC STUDY OF THE HEAD

Canine Plain and post contrast studies are available for review.

COMPUTED TOMOGRAPHIC FINDINGS

BREED
Rottweiler
The CT study reveals a large irregular shaped and ill-defined soft tissue attenuating mass of ~ 7.5 by 7 by 6 cm with multilobulated appearance arising from the left maxillary alveolar margin. The lesion demonstrates heterogeneous enhancement and irregular margins. The mass extends beyond the oral cavity into the left and right nasal cavities, including the nasal fundus, presphenoidal sinus, left orbit causing left exophthalmia and left masticatory muscles. Aggressive osteolysis of the left maxillary palatine, hard palate, orbital, presphenoidal and left zygomatic bones is seen.

SEX

MN

Mild enlargement of the left submandibular and retropharyngeal lymph nodes is noted.

AGE

2yr

Evidence of intracranial extension is not seen.

COMPUTED TOMOGRAPHIC DIAGNOSIS

INTERPRETED BY

Nele Eley (Ondreka),
DVM Dr. med. vet.,
DipECVDI

- Extensive left maxillary fibrosarcoma, highly invasive with extension into the left and right nasal cavities, nasal fundus, left orbit and left masticatory region.
- Mild regional lymphadenopathy- likely reactive.

INTERPRETATION OF FINDINGS & FURTHER RECOMMENDATIONS

HOSPITAL NAME

Loxahatchee Grove
Veterinary Clinic

A locally aggressive invasive oral fibrosarcoma with extension into adjacent nasal cavities, orbit and cranial bones is seen. The degree of bone lysis and soft tissue extension makes surgical excision difficult or unfeasible. Mild lymph node enlargement raises the concern for regional metastasis. However, at this point, reactive hyperplasia is considered more likely.

Oncology consultation and FNA of regional lymph nodes are recommended for further definition.

REFERRING VET

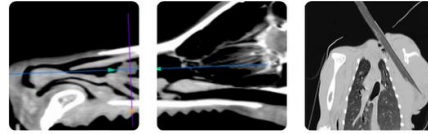
Dr. Yanguas

INVOICE

23101

DATE

12/03/2025



PATIENT

Brody Spagna

SPECIES

Canine

BREED

Rottweiler

SEX

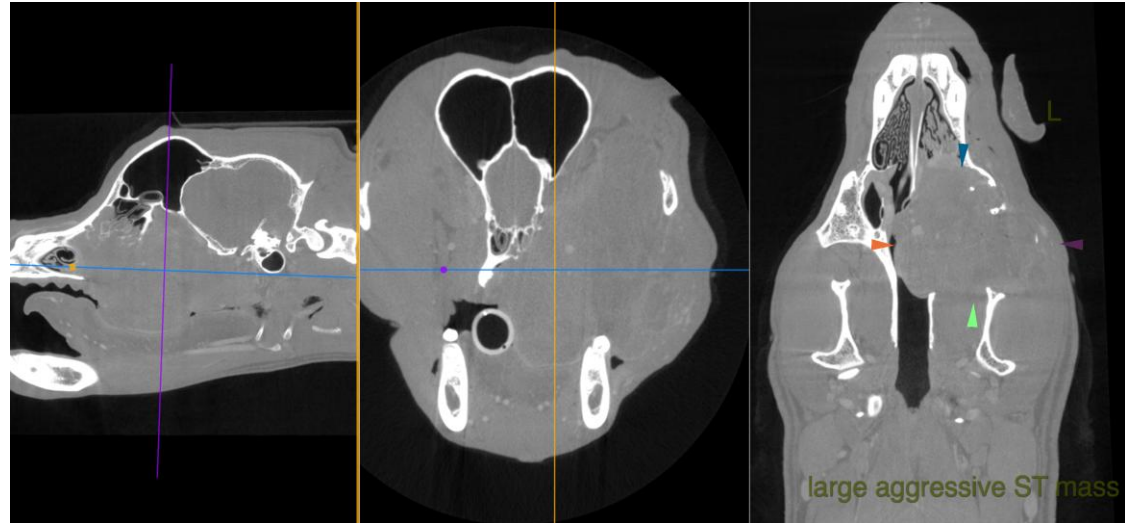
MN

AGE

2yr

INTERPRETED BY

Nele Eley (Ondreka),
DVM Dr. med. vet.,
DipECVDI



The information and recommendations provided are based on the images presented by the referring veterinarian. No evaluation can be communicated regarding pathology that was not visible in the image/video clips provided.

Thank you for this referral. If the clinical or image interpretation does not parallel your findings or if I can be of any further assistance please contact me.

Nele Eley (Ondreka), DVM, Dr. med. vet., DipECVDI
European Specialist in Veterinary Diagnostic Imaging, Cert. Radiology,
Senior lecturer University of Giessen/Germany, Veterinary Faculty, Department of Radiology.
info@sonopath.com

HOSPITAL NAME

Loxahatchee Grove
Veterinary Clinic

REFERRING VET

Dr. Yanguas

INVOICE

23101

DATE

12/03/2025